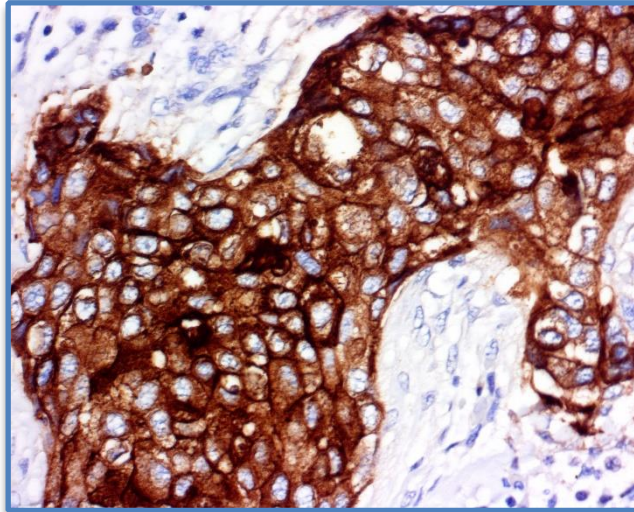
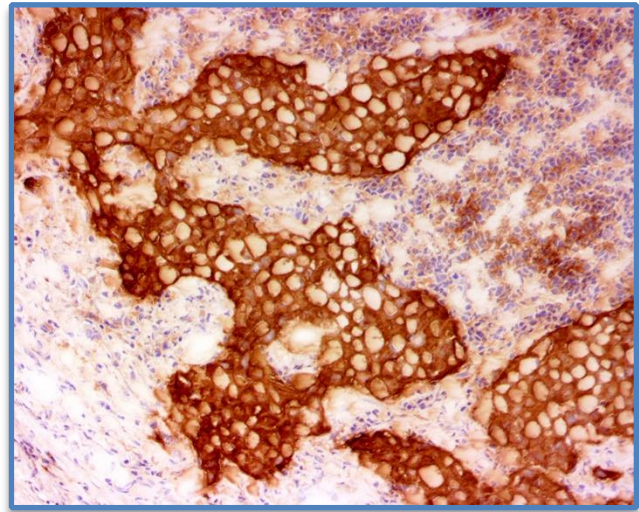




ihcDirect[®] EMA Ab Reagent Anti-Human EMA (MUC1, CA15-3) (Clone C137)



Breast Cancer, FFPE Tissue



Breast Cancer, Frozen Tissue

- Catalog Numbers: K31040-XXX, goes with ihc DAB 1:1 Kit K50002-### or DAB Kit, K50001-### and ihc Blocker K51001-### (Intl.) or K51002-### (USA)
- Package Size: (XXX) -005: For ~50 IHC Tests using frozen or FFPE tissues
-010: For ~100 IHC Tests using frozen or FFPE tissues
- Antibody: Mouse
- Storage: Store at 4°C upon receiving. DO NOT FREEZE.
- Intended Use: For *In Vitro* Diagnostic Use

Polymerized horseradish peroxidase (polyHRP)-labeled anti-human Epithelial Membrane Antigen (EMA, Clone C137) antibody is intended for laboratory use to qualitatively identify by light microscopy the presence of EMA in sections of formalin-fixed, paraffin-embedded (FFPE) and/or frozen tissues (FT) using immunohistochemistry (IHC) test method. The clinical interpretation of any staining or its absence should be complemented by morphological studies using proper controls and should be evaluated within the context of the patient's clinical history and other diagnostic tests and proper controls interpreted by a qualified pathologist and/or physician. This conjugate has been pre-diluted and optimized for IHC use without further dilution.

The ihcDirect[®] EMA Ab is a broad-spectrum antibody conjugate that recognizes Epithelial Membrane Antigen, a large cell surface mucin O-glycosylated protein expressed by glandular and ductal epithelial cells and some hematopoietic cell lines for tissues that form mucous barriers on epithelial surfaces. EMA is reactive against many types of adenocarcinoma and can be useful in recognizing epithelial derivation of poorly differentiated malignant tumors. EMA is strongly positive for breast and skin adnexal tumors. EMA is expressed by meningiomas, synovial sarcoma, epithelioid sarcoma, a subset of peripheral nerve sheath tumors, lymphocyte-predominant Hodgkin lymphoma, and anaplastic large-cell lymphoma (ALCL). Overexpression, aberrant intracellular localization, and changes in glycosylation of the associated protein have been associated with carcinomas. Staining is seen to a lesser degree in carcinomas of the cervix, colon, endometrium, kidney, lung, ovary, pancreas, prostate, stomach and thyroid while medullary carcinomas of the thyroid, squamous cell carcinomas, melanomas, sarcomas, and other lymphomas tend to be non-reactive.

